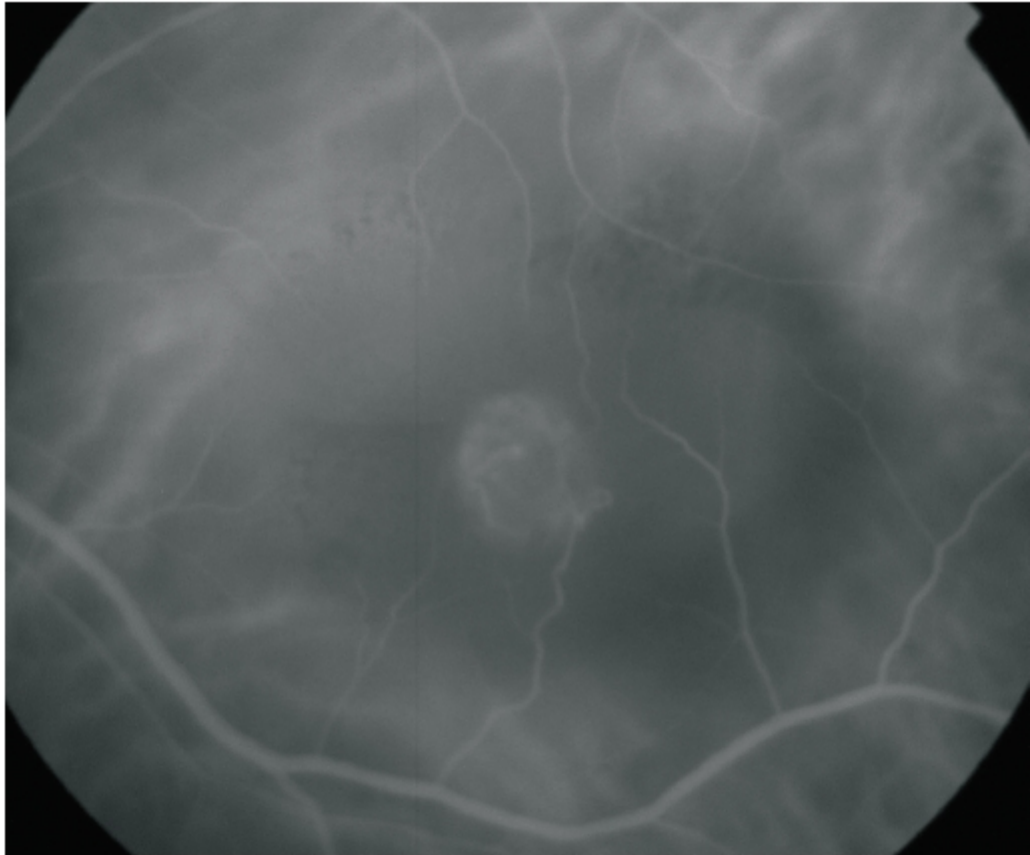


## Figure 2 - ICG.

Figure 2 - ICG.  
A RAP lesion with retinal-retinal anastomosis, an apparently intraretinal angiomatous mass and a serous PED.



[View PDF](#)